

# A Study on Morphometry and Morphological Variation of Suprascapular Notch in Dried Human Scapula

SUDARSHAN GUPTA, ZARNA PATEL, DEEPAK HOWALE

## ABSTRACT

**Introduction:** The Suprascapular Notch (SSN) is located at the superior border of the scapula, just medial to the base of the coracoid process. The knowledge of variations in shapes and dimensions can be helpful to clinicians to correlate the suprascapular nerve entrapment with a specific type of notch.

**Aim:** This study was carried out to observe morphological variation in shapes of SSN and morphometric analysis of SSN.

**Materials and Methods:** A total of 120 adult scapulae of unknown age and sex will be obtained from Department of Anatomy, GMERS Medical College, Gandhinagar and

Sola, Gujarat, India. The shapes of SSN were observed and dimensions were taken by digital Vernier caliper.

**Results:** The most common type of SSN observed was Type 2, a notch that was longest in its transverse diameter. The least common type was Type 4. Type 5 SSN was absent. The most common shape was 'J' and least common was 'V'. Partial and complete ossification was also noted.

**Conclusion:** Knowledge of anatomical variations of suprascapular notch is better for understanding location and source of entrapment syndrome. Since, the present study is performed with a limited number of dry scapulae, so there is need of further clinical, radiological and cadaveric studies.

**Keywords:** Ossified suprascapular ligament, Rotator cuff, Suprascapular nerve entrapment syndrome

## INTRODUCTION

The scapula in humans is located between second to seventh ribs in the post lateral part of the chest. It is a flat bone which is triangular in shape. At the superior border of scapula, a notch is present medially to coracoid process base. This notch is called the SSN. Suprascapular nerve passes through SSN which is motor nerve to supraspinatus and infraspinatus muscles, and sensory to rotator cuff muscles, ligamentous structures of shoulder and acromio-clavicular joint [1]. The suprascapular nerve passes through the suprascapular foramen which is created by the attachment of superior transverse scapular ligament to the notch [2].

Kopell and Thompson were the first to describe suprascapular nerve entrapment syndrome at SSN [3]. Over the years, many studies have investigated anatomical variations in the SSN and found out that ossified suprascapular ligament is one of the possible cause for development of suprascapular neuropathy [4]. It is characterised by shoulder pain, weakness in arm, difficulty in external rotation and abduction, and atrophy of supraspinatus and infraspinatus muscles. This syndrome is commonly seen in those who are involved in overhead heavy

work, athletes such as baseball players, volleyball players, weight lifters etc., [4]. The SSN was classified into six types by Rengachary et al., [5-7], based on the shape of notch.

This study has been planned with the following objectives:

- 1) To find out the prevalence of the various shapes of SSN.
- 2) Morphometric analysis of different shape of SSN and to find out the any difference in measurements of different shape and on right and left side scapulae.

## MATERIALS AND METHODS

This is an observational analytical type of study to determine the morphological variations and morphometric analysis of SSN in dried human scapulae conducted at Department of Anatomy of GMERS Medical College, Gandhinagar, Gujarat, India during September 2016 to December 2016 (4 Months). Using Epi Info 7 by CDC Atlanta [8], and considering a prevalence rate of variation in shape of SSN as 26.9% from previous studies [9], confidence level as 95%, acceptable margin of error as 8% and design effect of 1, the provisional sample size was calculated to be 120. These 120 human dried scapula of unknown age and sex were obtained

from Department of Anatomy, GMERS Medical College of Gandhinagar and GMERS Medical College Sola (Ahmedabad) after obtaining proper administrative and ethical clearance.

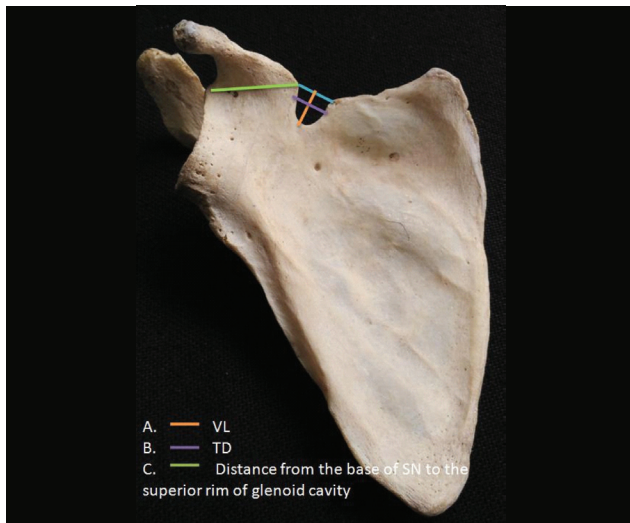
Only bones that were intact and free from any pathological or congenital anomalies were used.

The shape of SSN was observed on gross examination. According to the shape, the notch was classified as 'J', 'U', 'V' having indentation or notch completely absent. Partial/complete ossification of suprascapular ligament was also taken into account.

Anatomic measurements accurate to 0.1 mm were measured by a digital Vernier caliper. Vertical Length (VL), Transverse Diameter (TD) and distance from the base of SSN to the superior rim of glenoid cavity were measured [Table/Fig-1]. VL was the length between the midpoint of imaginary line joining the superior corners of the notch and maximal depth of the notch. The line perpendicular to the midpoint of VL was taken as the TD.

Nasis K et al., classified the SSN into five different types [3]:

1) Type 1: Without any discrete notch,



[Table/Fig-1]: Anatomic measurements of scapula.

2) Type 2: The notch that had longest transverse diameter,

3) Type 3: The notch that had longest vertical length,

4) Type 4: With a bony foramen, and

5) Type 5: With a notch and a bony foramen.

Photographs of different types of SSNs were also taken for record keeping purpose.

## RESULTS

[Table/Fig-2] shows the classification of SSN according to Natsis K et al., [3]. In this study, the most common type of SSN was Type 2 (66%), followed by Type 3 (18%) and Type 1

(13%). Least common type of SSN was Type 4 (3%). Type 5 SSN i.e., notch with bony foramen was not observed in any scapula.

Classification of SSN according to its shape is shown in [Table/Fig-3]. The most common type was 'J' (44%), followed by 'U' (22%), and 'V' (7%). Notch with indentation was found in 11%, whereas notch was completely absent in 8% of

Classification	n (%)
Type-1 (Without a discrete notch)	16 (13)
Type-2 (TD <sup>^</sup> >VL <sup>^</sup> )	79 (66)
Type-3 (VL>TD)	21 (18)
Type-4 (A bony foramen)	4 (3)
Type-5 (A notch and bony foramen)	0

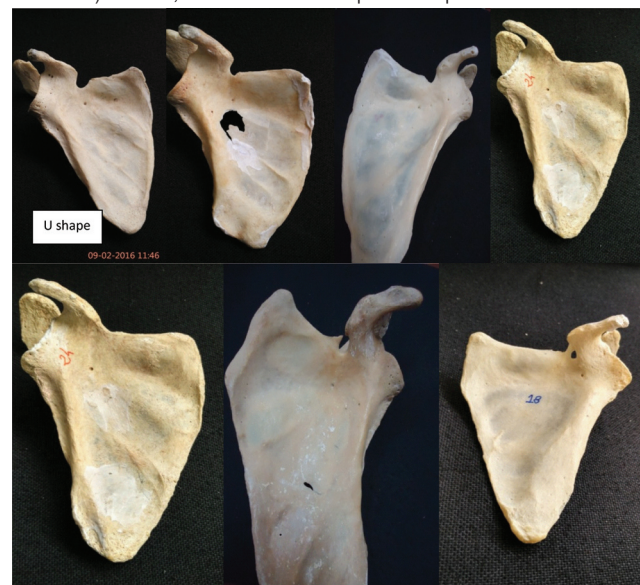[Table/Fig-2]: Classification of SSN as per Natsis K et al., [3] (n=120).

<sup>^</sup>TD – Transverse Diameter, <sup>^</sup>VL – Vertical Length

the scapula. Partial ossification was observed in 5% while complete ossification was observed in 3% of the scapula [Table/Fig-4].

[Table/Fig-5] shows the morphometric analysis of the SSN. The mean and standard deviation of vertical length, transverse diameter and distance from base of SSN to supraglenoid tubercle are noted. The mean of vertical length and transverse diameter of left scapula is significantly more than that of right scapula.

Morphometric measurements (vertical length, transverse diameter and distance from base of SN to supraglenoid tubercle) in 'U', 'V' and 'J' shaped scapula are shown in



[Table/Fig-3]: Scapula showing different shapes of notches (Top row, from left to right: 'U' shape, 'J' shape, 'V' shape, indentation. Bottom row, from left to right: absence of suprascapular notch, partial ossification of superior transverse scapular ligament, complete ossification of ligament).

Type of Shape	Right (%)	Left (%)	Total (%)
U	16 (27.6)	13 (21.0)	29 (24.2)
J	19 (32.8)	31 (50.0)	50(41.7)
V	06 (10.3)	03 (04.8)	09(07.5)
Indentation	07 (12.1)	06 (09.7)	13 (10.8)
Absent Notch	07 (12.1)	03 (04.8)	10 (08.3)
Ossification (Partial)	01 (01.7)	05 (08.1)	06 (05.0)
Ossification (Complete)	02 (03.4)	01 (01.6)	03 (02.5)
Total	58	62	120 (100%)

**[Table/Fig-4]:** Classification of suprascapular notch on the basis of its shape (n=120).

Parameter	Mean $\pm$ SD (mm)		p-value*
	Right scapula	Left scapula	
Vertical length (VL)	4.98 ( $\pm$ 1.75)	6.10 ( $\pm$ 1.71)	0.03
Transverse Diameter (TD)	6.33 ( $\pm$ 2.40)	7.62 ( $\pm$ 1.59)	0.04
Distance from Base of SSN to Supraglenoid Tubercle	25.93 ( $\pm$ 2.35)	25.39 ( $\pm$ 1.81)	0.12

**[Table/Fig-5]:** Morphometric analysis of suprascapular notch (n=120).

[Table/Fig-6]. The mean vertical length was significantly higher in 'U' shape and lower in 'J' shape. Similarly, mean transverse diameter was significantly higher in 'U' shape than 'V' shape. Post-hoc-test determined significant difference in mean vertical length between all three shapes. However, there was no significant difference in mean transverse diameter between 'V' and 'J' shaped scapula.

[Table/Fig-7] shows the shape-wise morphometric differences in right and left scapula. Mean vertical length was significantly higher in left 'U', 'V' and 'J' shaped scapula. All three shapes of left sided scapula also had significantly higher transverse diameter.

Parameter	Shapes of Scapula			p-value*
	'U' Shape	'V' Shape	'J' Shape	
Vertical Length (Mean mm)	8.09	6.73	6.09	0.04
Transverse Diameter (Mean mm)	9.62	7.55	7.60	0.03
Distance from Base of SSN to Supraglenoid Tubercle (Mean mm)	29.53	28.02	29.20	0.21

**[Table/Fig-6]:** Comparison of morphometry of scapula with various shapes of scapula (n=120).  
\*p value based on Student t test

Parameter	Shape	Mean $\pm$ SD (mm)		p-value*
		Right Scapula	Left Scapula	
Vertical Length (VL)	U	7.75	8.25	0.02
	V	6.11	7.35	0.01
	J	5.58	6.60	0.02
Transverse Diameter (TD)	U	9.24	10.00	0.04
	V	7.11	7.99	0.04
	J	7.20	8.00	0.03
Distance from Base of SSN to Supraglenoid Tubercle	U	30.40	28.66	0.19
	V	28.48	27.56	0.21
	J	29.83	28.57	0.20

**[Table/Fig-7]:** Shape wise morphometric differences in right and left scapula (n=120).

\*p value is based on one way Analysis of Variance (ANOVA) with post-hoc test

## DISCUSSION

In this study, according to Natsis K et al., classification [3], we observed four different types of SSN with varying percentages. Type 5 notch was not observed. Hardlicka, 1942 [4] was first to separate the SSNs into five types. Rengachary et al., [5-7] classified the SN into six types. Type 6 is complete ossification of ligament resulting in a bony foramen of variable size. This classification was modified by Ticker JB et al., [10] and Bayramoglu A et al., [11] and included the 'U', 'V' shape and notch with ossification.

Polgaj M et al., [12] elaborated a different classification in which three distances were measured: the maximal depth, superior and middle transverse diameter. The prevalence of completely ossified superior transverse scapular ligament was 10% as found in a study by Kannan U et al., [13]. Chabra N et al., [14] in their study did not found any Type 5 notch whereas, Type 2 was most common. Similar observations were found in present study. Wang HJ et al., [15] found proportion of completely ossified suprascapular ligament was 2.4%. Iqbal K et al., [16] reported 'J' shaped notch as the most common type (22%). Agrawal D et al., Patel P et al., and Sutaria L et al., found 'U' shaped notch at respectively 45%, 47.5%, 38% [17-19].

[Table/Fig-8,9] shows comparison of morphological variations in SN in present study viz-a-viz other previous studies. However, the present study takes a step further in comparing morphometry of scapula with various shapes, and their differences in left and right scapula.

Shape of bone is determined by morphogenetic factors and effect of strain also plays a major role in it. When mechanical or gravitational stresses are reduced or bone subjected to constant pressure, bone resorption occurs. On the other hand constant tension favours bone deposition. If force is applied to skeletal tissues they are able to adapt to their

Type of Suprascapular Notch	Kumar A et al., [20]	Natsis K et al., [3]	Wang HJet al., [15]	Chabra N et al., [14]	Present study
Type-1	32.46%	8.3%	28%	11.1%	13%
Type-2	50%	41.85%	58.16%	47.6%	66%
Type-3	7.84%	41.5%	28.23%	38.9%	18%
Type-4	9.70%	7.3%	3%	2.4%	3%
Type-5	None	0.7	None	None	None

**[Table/Fig-8]:** Comparison of types of suprascapular notch in present study with previous studies.

Shape of Suprascapular Notch	Iqbal K et a., [16]	Polguy Met al., [12]	Soni G et al., [21]	Vasudha TK et al., [22]	Present study
U	13.2	24.4	58	6.08	24.16
V	20	-	7	-	7.5
J	22	-	27	19.13	41.66
Indentation	33.5	-	3	7.82	10.84
Absent	22.5	-	2	6.08	18.34
Partial Ossification	-	-	14	6	5
Complete Ossification	-	-	-	-	2.5

**[Table/Fig-9]:** Comparison of shapes of suprascapular notch in present study with previous studies.

mechanical properties to match with the applied force. In case of increased strain, cells detect it and respond by deposition of more extracellular matrix by which stiffness of the tissue increases and strain level returns to normal. In similar way reduced strain leads to decrease production of extracellular matrix, decrease stiffness, so strain increases to normal level [23].

Scapula develops from a cartilaginous model. It ossified from eight or more ossification centers: one in the body, two in the coracoid process, two in the acromion, one each in the medial border, inferior angle and lower part of the rim of the glenoid cavity. The centre for the body appears in the eighth intrauterine week. In most persons, ossification starts in the coracoid process in the first year of life. The coracoid process joins the rest of the scapula at about the 15<sup>th</sup> year. At or after puberty, ossification also occurs in sub coracoid part, lower part of glenoid cavity, in the acromion process and medial border. The upper third of glenoid cavity is ossified from sub coracoid centre. In males this unites with rest of scapula at 17<sup>th</sup> year and in females at 14<sup>th</sup> year. By 20<sup>th</sup> year, the various epiphyses have all joined the scapula [23].

Scapula is a flat bone. Near its superior border it provides attachment to levator scapulae, supraspinatus, inferior belly of omohyoid and subscapularis muscle. Scapular attachment of levator scapulae on medial border extends from superior angle to medial end of scapular spine. Subscapularis arises from medial two-thirds of the costal surface of the scapula. Supraspinatus arises from medial two-thirds of supraspinous fossa and the supraspinous fascia. Inferior belly of omohyoid is attached near the SSN and occasionally from the superior

transverse scapular ligament. The hyoid bone is depressed by the inferior belly of omohyoid. This muscle is contracted in prolonged inspiratory effort which creates tension in lower part of deep cervical fascia and reduces the tendency of the soft part to be sucked inward [23].

Scapula provides attachment of various muscles that act on the shoulder girdle and shoulder joint. Traction and force applied by these muscles near the superior border may modify the shape of SSN. That lies near the junction of subcoracoid epiphysis and body of the scapula and this area is completely ossified in 14<sup>th</sup> year in the female and the 17<sup>th</sup> year in the male [23].

## CONCLUSION

Knowledge about anatomical variations of SSN is helpful for considering the location and source of entrapment syndrome. Variation in morphometry in left and right-sided scapula as well as in different shapes of scapula could be expected. As scapula is a flat bone and various muscles are attached to it, traction force applied by these muscles during movement of shoulder girdle and shoulder joint may lead to some variation in the morphology of scapula. The knowledge of these variations would be helpful during surgical and arthroscopic shoulder procedures. The sample size of human scapula was relatively limited in the present study, so there is scope for further studies focusing on clinical and radiological correlations.

## ACKNOWLEDGEMENTS

We sincerely thank the Heads of Department of Anatomy of GMERS Medical College, Sola and Gandhinagar for granting permission to carry out this study.

## REFERENCES

- [1] Kopell HP, Thompson WA. Pain and the frozen shoulder. *Surgery, Gynecology & Obstetrics*. 1959;109(1):92-96.
- [2] Rengachary SS, Neff JP, Singer PA, Brackett CE. Suprascapular entrapment neuropathy: a clinical, anatomical, and comparative study: part 1: clinical study. *Neurosurgery*. 1979;5(4):441-46.
- [3] Natsis K, Tottis T, Tsikarakis P, Appell HJ, Skandalakis P, Koebe J. Proposal for classification of the SSN: A study on 423 dried scapulas. *Clinical Anatomy*. 2007;20:135-39.
- [4] Hardlika A. The scapula-visual observations. *Am J Phys Antropol*. 1942;29:73-94.
- [5] Rengachary SS, Burr D, Lucas S, Hassanein KM, Mohn MP, Matzke H. Suprascapular entrapment neuropathy: a clinical, anatomical, and comparative study. Part 1: Clinical study. *Neurosurgery*. 1979;5(4):441-46.
- [6] Rengachary SS, Burr D, Lucas S, Hassanein KM, Mohn MP, Matzke H. Suprascapular entrapment neuropathy: a clinical, anatomical, and comparative. Study Part 2: anatomical study. *Neurosurgery*. 1979;5(4):447-51.
- [7] Rengachary SS, Burr D, Lucas S, Brackett CE. Suprascapular entrapment neuropathy: A clinical, anatomical, and comparative study. Part 3. *Neurosurgery*. 1979;5(4):452-55.
- [8] Centers for Disease Control and Prevention. Epi Info version 3.5.1, 2008. Available from: [www.cdc.gov/epiinfo](http://www.cdc.gov/epiinfo)
- [9] Sangam MR, Sarada Devi SS, Krupadanam K, Anasuya K. A study on the morphology of the suprascapular notch and its distance from the glenoid cavity. *J Clinic Diagn Res*. 2013;7(2):189-92.
- [10] Ticker JB, Djurasovic M, Strauch RJ, April EW, Pollock RG, Flatow EL, et al. The incidence of ganglion cysts and other variations in anatomy along the course of the suprascapular nerve. *Journal of Shoulder and Elbow Surgery*. 1998;7(5):472-78.
- [11] Bayramoglu A, Demiryürek D, Tüccar E, Erbil M, Aldur MM, Tetik O, et al. Variations in anatomy at the suprascapular notch possibly causing suprascapular nerve entrapment: an anatomical study. *Knee Surgery, Sports Traumatology, Arthroscopy*. 2003;11(6):393-98.
- [12] Polguj M, Jedrzejewski KS, Podgorski M, Topol M. Correlation between morphometry of suprascapular notch and anthropometric measurements of the scapula. *Folia Morphol*. 2011;70:109-15.
- [13] Kannan U, Kannan NS, Anbalagan J, Rao S. Morphological study of suprascapular notch in Indian dry scapulae with specific reference to the incidence of completely ossified superior transverse scapular ligament. *J Clin Diagn Res*. 2014;8(3):07-10.
- [14] Chhabra N, Prakash S, Ahuja MS. Morphometry and morphology of supra scapular notch: its importance in suprascapular nerve entrapment. *Int J Anat Res*. 2016;4(3):2536-41.
- [15] Wang HJ, Chen C, Wu LP, Pan CQ, Zhang WJ, Li YK. Variable morphology of the suprascapular notch: an investigation and quantitative measurements in Chinese population. *Clinical Anatomy*. 2011;24(1):47-55.
- [16] Iqbal K, Iqbal R. Anatomical variations of suprascapular notch in scapula. *J Morphol Sci*. 2010;27(1):01-02.
- [17] Agrawal D, Singh B, Agrawal GA. Human scapulae; Suprascapular notch, morphometry and variations. *Indian Jour Clin Anat & Physio*. 2014;1(1):01-07.
- [18] Patel P, Patel SV, Patel SM, Badal J, Chavda S, Patel D. Study of variations in the shape of the suprascapular notch in Dried Human Scapula. *Int J Biol Med Res*. 2013;4(2):3162-64.
- [19] Sutaria LK. Morphology and morphometric analysis of suprascapular notch. *IJBAR*. 2013;4(1):35-39.
- [20] Kumar A, Sharma A, Singh P. Anatomical study of the suprascapular notch: quantitative analysis and clinical considerations for suprascapular nerve entrapment. *Singapore Medical Journal*. 2014;55(1):41.
- [21] Soni G, Malik VS, Boddeti RK. Morphometric analysis of suprascapular notch: review of literature. *Int J Anat Res*. 2015;3(4):1624-28.
- [22] Vasudha TK, Shetty A, Gowd S, Rajasekhar SS. Morphological study on suprascapular notch and superior transverse scapular ligaments in human scapulae. *International Journal of Medical Research & Health Sciences*. 2013;2(4):793-98.
- [23] Standring S, editor. *Gray's anatomy: the anatomical basis of clinical practice*, 40<sup>th</sup> Edition. Elsevier Health Sciences; 2015.

### AUTHOR(S):

1. Dr. Sudarshan Gupta
2. Dr. Zarna Patel
3. Dr. Deepak Howale

### PARTICULARS OF CONTRIBUTORS:

1. Associate Professor, Department of Anatomy, GMERS, Gandhinagar, Gujarat, India.
2. Assistant Professor, Department of Anatomy, GMERS, Gandhinagar, Gujarat, India.
3. Professor and Head, Department of Anatomy, GMERS, Valsad, Gujarat, India.

### NAME, ADDRESS, E-MAIL ID OF THE CORRESPONDING AUTHOR:

Dr. Zarna Patel,  
Assistant Professor, Department of Anatomy,  
GEMRS Medical College,  
Gandhinagar-382012, Gujarat, India.  
E-mail: [zdpdoctor@yahoo.com](mailto:zdpdoctor@yahoo.com)

### FINANCIAL OR OTHER COMPETING INTERESTS:

None.

Date of Publishing: Jul 01, 2017